Michael Cormier – The Breitbart Toe Tag PART II: (Andrew Breitbart's Autopsy & Cyanide)

EXIT 9 Investigations: Series 1 – Michael Cormier (The Breitbart Toe Tag PART II: Andrew Breitbart's Autopsy & Cyanide)

THE BREITBART CORONER BOOK IS NOW AVAILABLE



Part I showcased our evidence proving Michael Cormier did assist on a private autopsy of Andrew Breitbart. Part II of our investigation provides an in-depth analysis of Andrew Breitbart's death and autopsy.

- *The Breitbart Autopsy Results.*
- *The Usage of Potassium Cyanide in homicides/assassinations.*

- *The Similarities of Potassium Cyanide poisonings and Andrew Breitbart's death.*

- *The Half-Life & Effects of Cyanide.*

*Don't forget to **subscribe to our mailing list**. We send exclusive content to all our members.

THE BREITBART AUTOPSY RESULTS

On the official Andrew Breitbart autopsy, it shows that **"comprehensive testing**" was requested on the toxicological analysis and for Breitbart's heart blood to be analyzed for cyanide poisoning. Under "**Toxicology Requests**" the "**Comprehensive Toxicological Screen**" is checked – and "**Other (Specify drug and tissue)**" is labeled "**Cyanide."** The LA Coroner's Office had no reason to test for cyanide — this request had to come from the family.

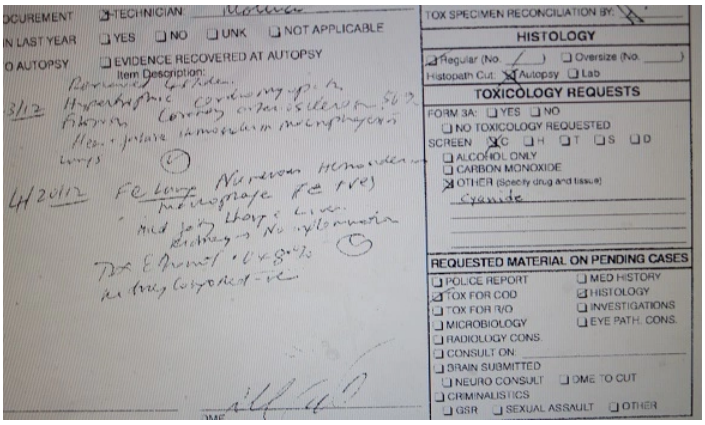
TOX SPECIMEN RECONCILIATION BY:
HISTOLOGY
Regular (No.) Oversize (No.)
Histopath Cut: Autopsy Lab
TOXICOLOGY REQUESTS
FORM 3A: YES NO
NO TOXICOLOGY REQUESTED
SCREEN C H T S D
ALCOHOL ONLY
CARBON MONOXIDE
OTHER (Specify drug and tissue)
Cyanide
REQUESTED MATERIAL ON PENDING CASES
POLICE REPORT
TOX FOR COD
TOX FOR R/O
MICROBIOLOGY
RADIOLOGY CONS.
CONSULT ON:
BRAIN SUBMITTED
NEURO CONSULT
CRIMINALISTICS
GSR
SEXUAL ASSAULT
OTHER
MED HISTORY
HISTOLOGY
INVESTIGATIONS
EYE PATH. CONS.
DME TO CUT

In the toxicology report, cyanide is not detected; this analysis was conducted by **M. Schuchardt** and signed-off by**Supervising Criminalist Dan Anderson.**

interpretations of the Analyst:

Coroner Case Number: 2012-01471 **Decedent:** BREITBART, ANDREW JAMES

SPECIMEN	SERVICE	DRUG	RESULT	ANALYST
Blood, Femoral				
	Alcohol	Ethanol	0.04 g%	M. Schuchardt
Blood, Heart				
	Alcohol	Ethanol	0.04 g%	M. Schuchardt
	Bases	Basic Drugs	ND	S. DeQuintana
	Cyanide	Cyanide	ND	M. Schuchardt
	ELISA	Acetaminophen	ND	C. Miller
	ELISA	Barbiturates	ND	C. Miller
	ELISA	Benzodiazepines	ND	C. Miller
	ELISA	Cocaine and Metabolites	ND	C. Miller
	ELISA	Fentanyl	ND	C. Miller
	ELISA	Methamphetamine & MDMA	ND	C. Miller
	ELISA	Opiates: Codeine & Morphine	ND	C. Miller
	ELISA	Opiates: Hydrocodone & Hydromorphone	ND	C. Miller
	ELISA	Phencyclidine	ND	C. Miller
	ELISA	Salicylate	ND	C. Miller
	Halogenated Hydrocarbons	Ethchlorvynol	ND	S. DeQuintana

ng/g	Nanograms per Gram	ug/g	Micrograms per Gram
ng/mL	Nanograms per Milliliter	ug/mL	Microgram per Milliliter

nt's Evidence Retention Policy, the blood specimen(s) will be retained for one-year and all other specimens for six-m

inistratively reviewed by:

Daniel T. Anderson, M.S., FTS-Ab
Supervising Criminalist II
TOXICOLOGY

Andrew Breitbart's heart weighed 720 grams. The average size heart of a healthy adult male is 300 grams.

CARDIOVASCULAR SYSTEM:

The aorta is elastic and of even caliber throughout with vessels distributed normally from it. Both abdominal and thoracic aorta have minimal lipid streaking. There is no tortuosity or widening of the thoracic segment. The abdominal aorta has no atherosclerosis. There is no dilation of the lower abdominal segment. No aneurysm is present. The major branches of the aorta show no abnormality.

Within the pericardial sac there is a minimal amount of serous fluid. The heart weighs 720 grams. It has left ventricular hypertrophy. The right ventricle is 0.3 cm thick and the left ventricle is 2.2 cm thick. The chambers are normally developed and are without mural thrombosis. The valves are thin, leafy and competent. The circumference of the valve rings are: Tricuspid valve 12.8 cm, pulmonic valve 8.8 cm, mitral valve 13.2 cm and aortic valve 8 cm. There is no endocardial discoloration. There is a dusky red discoloration of the lateral wall of the left ventricle. There is no abnormality of the apices of the papillary musculature. There are no defects of the septum, however the septum is thickened at 3.2 cm. The great vessels enter and leave in a normal fasnion. The coronary ostia are widely patent. There is a balanced pattern of coronary artery distribution. There is segmental atherosclerosis with 70 to 80% narrowing of the anterior descending branch of the left coronary artery and a tributary. No focal endocardial, valvular or myocardial lesions are seen. The blood within the heart and large blood vessels is liquid.

According to Andrew Breitbart's wife in the autopsy's investigation witness statement– he was previously diagnosed with congestive heart failure and two weeks earlier had the flu.

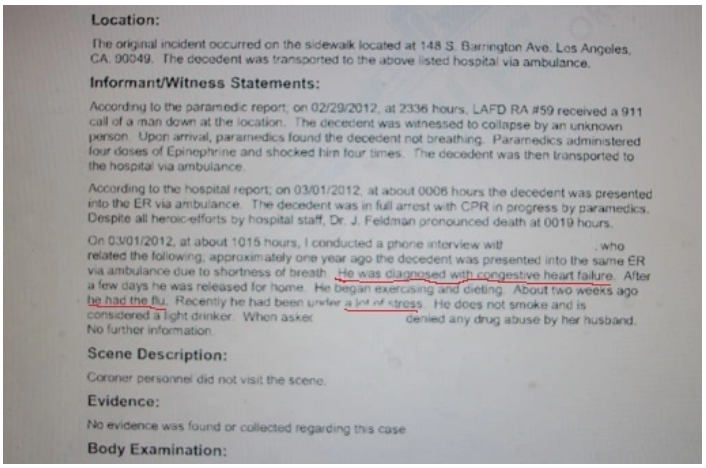

Location:

The original incident occurred on the sidewalk located at 148 S. Barrington Ave. Los Angeles, CA. 90049. The decedent was transported to the above listed hospital via ambulance.

Informant/Witness Statements:

According to the paramedic report; on 02/29/2012, at 2336 hours, LAFD RA #59 received a 911 call of a man down at the location. The decedent was witnessed to collapse by an unknown person. Upon arrival, paramedics found the decedent not breathing. Paramedics administered four doses of Epinephrine and shocked him four times. The decedent was then transported to the hospital via ambulance.

According to the hospital report; on 03/01/2012, at about 0006 hours the decedent was presented into the ER via ambulance. The decedent was in full arrest with CPR in progress by paramedics. Despite all heroic efforts by hospital staff, Dr. J. Feldman pronounced death at 0019 hours.

On 03/01/2012, at about 1015 hours, I conducted a phone interview with , who related the following; approximately one year ago the decedent was presented into the same ER via ambulance due to shortness of breath. He was diagnosed with congestive heart failure. After a few days he was released for home. He began exercising and dieting. About two weeks ago he had the flu. Recently he had been under a lot of stress. He does not smoke and is considered a light drinker. When asked denied any drug abuse by her husband. No further information.

Scene Description:

Coroner personnel did not visit the scene.

Evidence:

No evidence was found or collected regarding this case

Body Examination:

A tweet on Andrew Breitbart's Twitter timeline confirms the flu.

AndrewBreitbart @AndrewBreitbart · 16 Feb 2012

Replying to @FishbowlDC

Atkins mixed with head cold (lack of appetite) transforming me into waif-like figure virtually overnight! @FishbowlDC

1

Andrew Breitbart's death is officially contributed to natural causes due to the onset of heart failure.

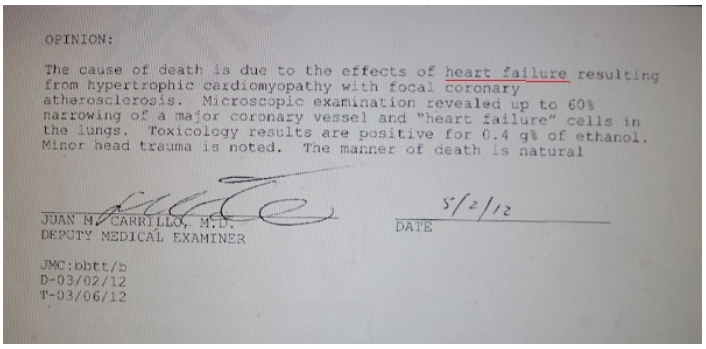

OPINION:

The cause of death is due to the effects of heart failure resulting from hypertrophic cardiomyopathy with focal coronary atherosclerosis. Microscopic examination revealed up to 60% narrowing of a major coronary vessel and "heart failure" cells in the lungs. Toxicology results are positive for 0.4 g% of ethanol. Minor head trauma is noted. The manner of death is natural

JUAN M. CARRILLO, M.D.
DEPUTY MEDICAL EXAMINER

5/2/12
DATE

JMC:bbtt/b
D-03/02/12
T-03/06/12

THE USAGE OF POTASSIUM CYANIDE IN HOMICIDES/ASSASSINATIONS

POTASSIUMCYANIDE

As described by **Pubchem.ncbi**:

"POTASSIUM CYANIDE is a highly poisonous compound that is an inhibitor of many metabolic processes but has been shown to be an especially potent

inhibitor of heme enzymes and hemeproteins. It is used in many industrial processes."

Potassium Cyanide is a rare substance to use for murder and has factors that often resemble a heart attack. Externally the body varies in appearance; descriptions of a bright red face, especially the chest and neck are some signs of cyanide poisoning. The redness of the skin is a side effect of the tissue not receiving oxygen. Although the scent of almonds is associated with potassium cyanide, nearly 60% of the population can't detect the distinct smell. This is linked to a sex-link genetic, which mostly affects males. A teaspoon of cyanide is enough to kill an adult male, and it's available in many forms including liquid, powder, and gas.

The case of Chicago lottery winner Urooj Khan is a perfect example of cyanide and how it's short half-life contributes to the false analysis of toxicology reports.

In March 2013, Urooj had dinner and collapsed soon after. His death was ruled "heart failure." The case was closed. Urooj Khan's brother opened a new interest in the investigation when he requested the body be tested for poison. A fatal dose of

cyanide was found in a sample from **Khan's body**.



Potassium cyanide has a long history within the realm of assassinations.**Bohdan Stashynsky** is a former KGB operative who **assassinated** two Ukrainian nationalists (**Lev Rebet** and **Stepan Bandera**) in the 1950s. He performed the killings with the use of a spray gun that fired a cloud of gas laced from a crushed cyanide capsule. The poisonous gas was designed with the intentions of making the murders look like a heart attack.
The **device** was used by Lev Rebet in 1957, and a new version of the gun was implemented in the death of Stepan Bandera in 1959.

Richard Kuklinski (The Iceman Killer) was a hitman for American crime families of Newark, New Jersey, and the five mafia families of New York City. During **America**

Undercover's 1992 The Iceman Tapes; Kuklinski makes mention of using cyanide in restaurants to make deaths look like a heart attack. He also would spill a cyanide-laced drink on his victims at nightclubs, the poisonings virtually undetected due to the cyanide's ability to be absorbed by the skin through the clothing, causing death.

SIMILARITIES OF A POTASSIUM CYANIDE CASE & ANDREW BREITBART'S DEATH

In a potassium cyanide case presented in "***The Boston Medical and Surgical Journal***," in January 1870; we found similarities that correlate to Andrew Breitbart's autopsy results.

The story below is about an "**Unidentified man**" who mistakenly consumed potassium cyanide. Initially, his death was thought to be from a fall or natural causes. An autopsy revealed more.

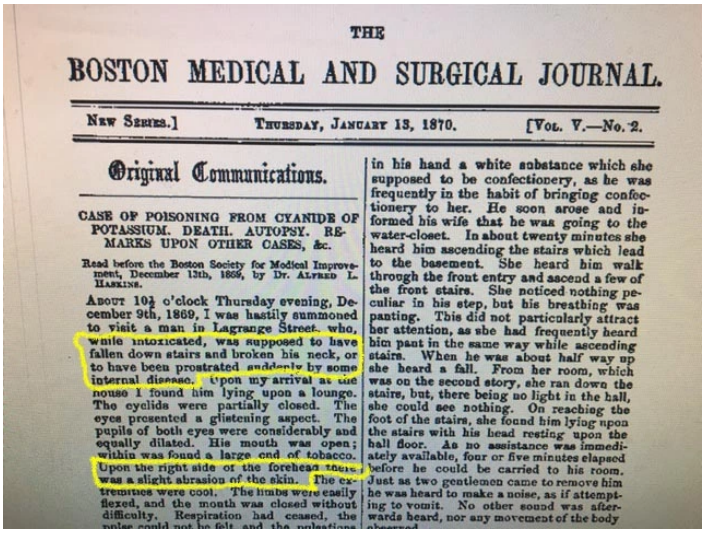

THE

BOSTON MEDICAL AND SURGICAL JOURNAL.

New Series.] Thursday, January 13, 1870. [Vol. V.—No. 2.

Original Communications.

CASE OF POISONING FROM CYANIDE OF POTASSIUM. DEATH. AUTOPSY. REMARKS UPON OTHER CASES, &c.

Read before the Boston Society for Medical Improvement, December 13th, 1869, by Dr. Alfred L. Haskins.

About 10½ o'clock Thursday evening, December 9th, 1869, I was hastily summoned to visit a man in Lagrange Street, who, while intoxicated, was supposed to have fallen down stairs and broken his neck, or to have been prostrated suddenly by some internal disease. Upon my arrival at the house I found him lying upon a lounge. The eyelids were partially closed. The eyes presented a glistening aspect. The pupils of both eyes were considerably and equally dilated. His mouth was open; within was found a large end of tobacco. Upon the right side of the forehead there was a slight abrasion of the skin. The extremities were cool. The limbs were easily flexed, and the mouth was closed without difficulty. Respiration had ceased, the pulse could not be felt, and the pulsations

in his hand a white substance which she supposed to be confectionery, as he was frequently in the habit of bringing confectionery to her. He soon arose and informed his wife that he was going to the water-closet. In about twenty minutes she heard him ascending the stairs which lead to the basement. She heard him walk through the front entry and ascend a few of the front stairs. She noticed nothing peculiar in his step, but his breathing was panting. This did not particularly attract her attention, as she had frequently heard him pant in the same way while ascending stairs. When he was about half way up she heard a fall. From her room, which was on the second story, she ran down the stairs, but, there being no light in the hall, she could see nothing. On reaching the foot of the stairs, she found him lying upon the stairs with his head resting upon the hall floor. As no assistance was immediately available, four or five minutes elapsed before he could be carried to his room. Just as two gentlemen came to remove him he was heard to make a noise, as if attempting to vomit. No other sound was afterwards heard, nor any movement of the body

Here we have the autopsy report of Andrew Breitbart. An abrasion on the right forehead, this would have resulted from his fall on the sidewalk.

The decedent is a 43-year-old Caucasian male who according to preliminary report collapsed at 148 S. Barrington Avenue in Westwood. 911 was called and the decedent was transported to Ronald Reagan UCLA Medical Center where despite medical intervention he was pronounced dead on 3/1/2012 at 0019 hours.

EXTERNAL EXAMINATION:

The body is identified by toe tags and is that of an unembalmed, refrigerated adult male Caucasian who appears slightly older tha the reported age of 43 years. The body weighs 251 pounds, measures 75 inches, and is moderately obese. A 1/4 inch diamete healing ulceration is noted to the dorsum of the right hand. There is a 2x1.5 inch contusion with 1/4 inch central abrasion noted to the right forehead. Also noted is a 1.5x1 inch hematoma of the left occipital scalp with central abrasion. Also noted is a 1.25x0.25 inch linear red abrasion to the left posterior shoulder. Tattoos are absent. Rigor is present. Livor mortis is posterior and dependent.

The head is normocephalic and covered by gray brown hair. There is mid biparietal balding and the hair can be described as short and wavy. Mustache and beard are absent. Examination of the eyes reveals irides that appear to be blue in color and sclera that are congested. There are no petechial hemorrhages of the conjunctivae of the lids or the sclera. The oronasal passages are unobstructed. Upper and lower teeth are present. The neck is unremarkable. There is no chest deformity. There is no increased anterior-posterior diameter. The abdomen is obese. The genitalia are those of an adult male. The penis appears circumcised. The external genitalia are without trauma or lesions. The extremities show no edema, joint deformity, abnormal mobility or needle tracks.

EVIDENCE OF THERAPEUTIC INTERVENTION:

Two men at the scene of the "**Unidentified man**," heard him attempting to vomit soon before death.

before he could be carried to his room. Just as two gentlemen came to remove him he was heard to make a noise, as if attempting to vomit. No other sound was afterwards heard, nor any movement of the body observed.

To my question, whether any medicine had been taken, a negative answer was given. An investigation of the localities which he had last visited revealed the following:—Upon a table in the basement a goblet was found, in which were about six drachms of a transparent liquid. At the bottom of the goblet were four or five small, hard, white, irregularly shaped masses. As the substance which was dissolved in the liquid had been deposited upon the

This is the [eyewitness statement by Chris Lasseter] about Breitbart's last moments. He describes a "**guttural sound**" that originated from Breitbart's stomach.

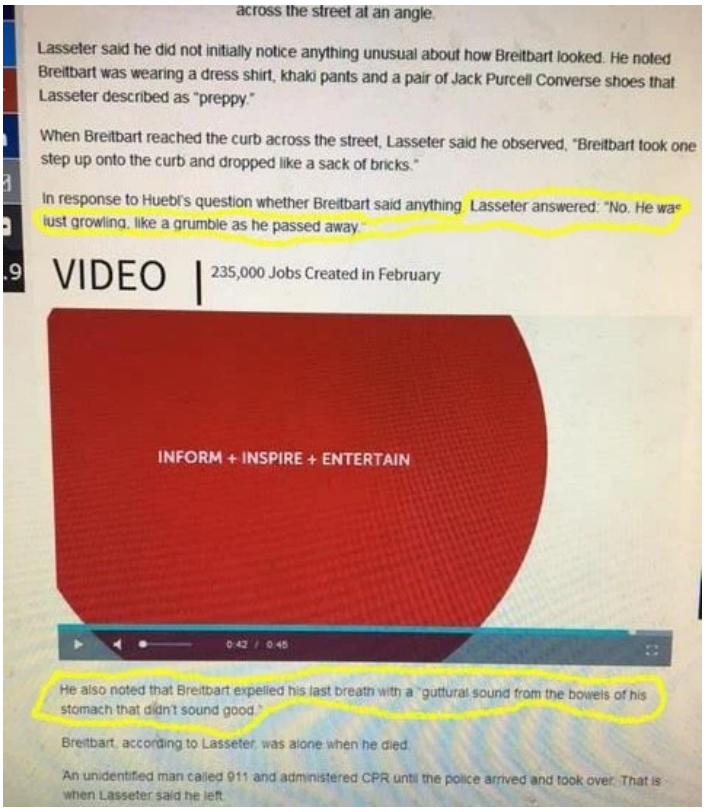

across the street at an angle.

Lasseter said he did not initially notice anything unusual about how Breitbart looked. He noted Breitbart was wearing a dress shirt, khaki pants and a pair of Jack Purcell Converse shoes that Lasseter described as "preppy."

When Breitbart reached the curb across the street, Lasseter said he observed, "Breitbart took one step up onto the curb and dropped like a sack of bricks."

In response to Huebl's question whether Breitbart said anything, Lasseter answered: "No. He was just growling, like a grumble as he passed away."

VIDEO | 235,000 Jobs Created in February

INFORM + INSPIRE + ENTERTAIN

0:42 / 0:46

He also noted that Breitbart expelled his last breath with a "guttural sound from the bowels of his stomach that didn't sound good."

Breitbart, according to Lasseter, was alone when he died.

An unidentified man called 911 and administered CPR until the police arrived and took over. That is when Lasseter said he left.

Contraction of the left side of the heart is most frequently found in deaths related to potassium cyanide.

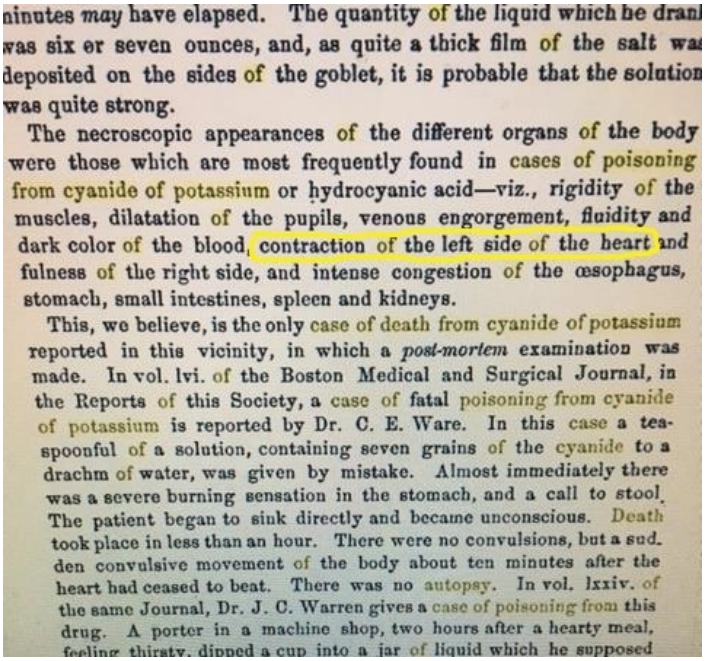

minutes *may* have elapsed. The quantity of the liquid which he drank was six or seven ounces, and, as quite a thick film of the salt was deposited on the sides of the goblet, it is probable that the solution was quite strong.

The necroscopic appearances of the different organs of the body were those which are most frequently found in cases of poisoning from cyanide of potassium or hydrocyanic acid—viz., rigidity of the muscles, dilatation of the pupils, venous engorgement, fluidity and dark color of the blood, contraction of the left side of the heart and fulness of the right side, and intense congestion of the œsophagus, stomach, small intestines, spleen and kidneys.

This, we believe, is the only case of death from cyanide of potassium reported in this vicinity, in which a *post-mortem* examination was made. In vol. lvi. of the Boston Medical and Surgical Journal, in the Reports of this Society, a case of fatal poisoning from cyanide of potassium is reported by Dr. C. E. Ware. In this case a teaspoonful of a solution, containing seven grains of the cyanide to a drachm of water, was given by mistake. Almost immediately there was a severe burning sensation in the stomach, and a call to stool. The patient began to sink directly and became unconscious. Death took place in less than an hour. There were no convulsions, but a sudden convulsive movement of the body about ten minutes after the heart had ceased to beat. There was no autopsy. In vol. lxxiv. of the same Journal, Dr. J. C. Warren gives a case of poisoning from this drug. A porter in a machine shop, two hours after a hearty meal, feeling thirsty, dipped a cup into a jar of liquid which he supposed

The left ventricle of Breitbart's heart showed extensive changes.

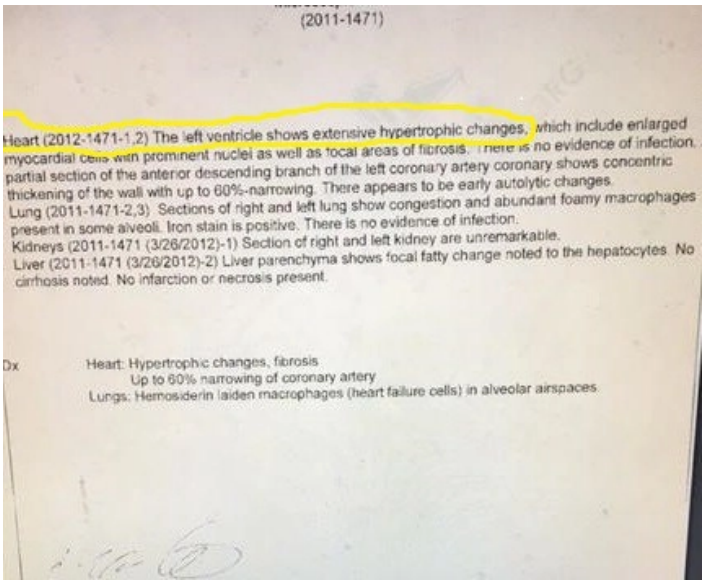

(2011-1471)

Heart (2012-1471-1,2) The left ventricle shows extensive hypertrophic changes, which include enlarged myocardial cells with prominent nuclei as well as focal areas of fibrosis. There is no evidence of infection. partial section of the anterior descending branch of the left coronary artery coronary shows concentric thickening of the wall with up to 60%-narrowing. There appears to be early autolytic changes.
Lung (2011-1471-2,3) Sections of right and left lung show congestion and abundant foamy macrophages present in some alveoli. Iron stain is positive. There is no evidence of infection.
Kidneys (2011-1471 (3/26/2012)-1) Section of right and left kidney are unremarkable.
Liver (2011-1471 (3/26/2012)-2) Liver parenchyma shows focal fatty change noted to the hepatocytes. No cirrhosis noted. No infarction or necrosis present.

Dx Heart: Hypertrophic changes, fibrosis
Up to 60% narrowing of coronary artery
Lungs: Hemosiderin laiden macrophages (heart failure cells) in alveolar airspaces

THE HALF-LIFE & EFFECTS OF CYANIDE

Andrew Breitbart's autopsy was performed on March 2, 2012, and his private autopsy on March 4, 2012 – with this length in-time between his initial death and the testing of Breitbart's blood, cyanide would be almost impossible to detect.

Assistant professor of criminal justice **Chi-Chung (Jorn) Yu** gives us a clue:

"**Due to the relatively short half-life of cyanide—from minutes to hours depending on the matrix—toxicological detection of cyanide to confirm cyanide poisoning may only be feasible within the first few hours following exposure," he said. "Moreover, the volatility and reactivity of cyanide leave direct measurements highly susceptible to errors introduced during the sample collection and separation step**."

"**Cyanide levels in blood samples taken at autopsy the next day have been reported to decrease by approximately 79 percent. Postmortem formation of cyanide may also occur and complicate**

the interpretation of cyanide results," he said. "Therefore, the presence of cyanide becomes less feasible when the detection window."

Cyanide effects explained by **Dr. John Butt**:

Chris Lasseter, the only eyewitness to Breitbart's death, stated:

"**His skin was red, but around his hairline, he had a white band around his forehead."**

"He was just growling, like a grumble as he passed away."

"**He made a guttural noise, just as he expelled his last breath, from the bowels of his stomach.**"

Cyanide symptoms include cherry-red/pink skin, loss of gait, gastro-discomfort, agitation and blanching of the skin (*due to loss of oxygen to the area and pressure*) – This could be the reasoning behind the "**white band**" around Breitbart's head. Breitbart could've placed his hand on his forehead due to dizziness, causing pressure thus turning his skin white.

Below is a **GRAPHIC** video of **Michael Marin's**cyanide death.

The likelihood that Andrew Breitbart died from something other than "**heart failure**" is present, but we will probably never know for sure about the cyanide — we do have more evidence in the case of **Michael Cormier**, which supports a greater narrative that something isn't right in Breitbart's autopsy.

Why would someone want to kill Andrew Breitbart? What is the connection to online Trolls and Andrew Breitbart? These questions are answered in **PART III**.

This is an official EXIT 9 investigation.

– **Press Graye**